

Protective action of hydroethanolic extract of *Moringa oleifera* flower on acetaminophen-induced hepatotoxicity in rats

Dr. Shyamal Kanti Das, Dr. Soumendra Nath Karmakar, Sampurna Roy

Department of Physiology, Krishnath College, (Affiliated to University of Kalyani, Berhampore), Murshidabad, West Bengal, India

Abstract

Background/Aims: The present study was to investigate the possible hepatoprotective action of the hydroethanolic extract of *Moringa oleifera* (MO) flowers in comparison to hepamerz (positive control) against long-term hepatotoxicity induced by acetaminophen (APAP) in albino Wistar rat (male). **Methods:** In this study, different groups of animals were treated with APAP (300 mg/kg body weight), both APAP (300 mg/kg body weight) and MO flower hydroethanolic extract (400 mg/kg body weight), both APAP (300mg/kg body weight) and hepamerz (150 mg/kg body weight), respectively. **Results:** Liver function tests were analyzed, and histopathological changes of liver were also observed along with antioxidant enzymes and lipid peroxidation. APAP-induced hepatotoxicity increases the serum glutamate oxaloacetate transaminase (SGOT), serum glutamate pyruvate transaminase (SGPT), alkaline phosphatase (ALP), and decreases the level of total serum protein, where significant decrease in SGOT, SGPT, and ALP and significant increase in total serum protein were observed in the MO flower hydroethanolic extract-treated animals. Oxidative stress was also observed in APAP treated group and reduction in stress was also noted after hepamerz and MO supplementation. **Conclusion:** It can be concluded that hydroethanolic extract of MO flower has potency as a hepatoprotective agent like hepamerz against APAP-induced hepatotoxicity on albino rats.

Key words: Acetaminophen, catalase, hepamerz, histopathology, oxidative stress

INTRODUCTION

Liver diseases are a major global concern, and this type of disease or disorder still has extremely poor prognosis and high mortality because of the lack of effective preventive measures and treatment options. Liver cirrhosis is a major public health problem. Based on autopsy studies, its prevalence is 4.5%–9.5% in the general population, which means that hundreds of millions of people are affected worldwide.^[1,2] Despite remarkable advances in the field of modern medicine, hepatic diseases remain a major public health problem; thus, the search for new effective medicines without side effects is still ongoing. Acetaminophen belongs to a class of drugs called analgesics and antipyretics. However, acetaminophen (APAP) is the most common cause of drug-induced liver diseases and acute liver failure in humans and experimental animals. It is used for the relief of fever as well as aches and pains associated

with many conditions. Acetaminophen is as effective as nonsteroidal anti-inflammatory drug. As a result of the high rate of abuse, APAP overdose is the common cause of drug-induced liver failure. Hepamerz is very common to be used as a drug to protect liver damage. Besides this common drug used for the protection of chemical-induced hepatic disorder, the attempt has been made in the present study with hydroethanolic extract of *Moringa oleifera* (MO) flower to protect the hepatic disorder. MO possesses a rich and rare combination of therapeutically-active components such as kaempferol, rhamnetin, quercetin, chlorogenic acid,

Address for correspondence:

Soumendra Nath Karmakar, Department of Physiology, Krishnath College, (Affiliated to University of Kalyani, Berhampore), Murshidabad, West Bengal, India.
E-mail: soumennnn@gmail.com

Received: 13-12-2018

Revised: 27-11-2019

Accepted: 20-12-2019

rutin, and apigenin, and is also enriched with an exogenous supply of ascorbic acid and carotenoids, which are renowned antioxidant components.^[3] Therapeutic use of MO edible parts in many regions of Africa as well as Asia, it is widely consumed for self-medication by patients affected by diabetes, hypertension, or HIV-AIDS.^[4] MO is the most widely distributed species of the Moringaceae family throughout the world, especially in Asian countries, having a remarkable range of pharmacological properties in addition to significant nutritional value. MO is a highly valued plant in tropic and subtropical countries where it is mostly cultivated.^[5] The therapeutic properties of MO hydroethanolic extracts act against acute liver injury by APAP.^[6] Moringa leaves act as a good natural source of antioxidants vitamins such as ascorbic acid, flavonoids, phenolics, and carotenoids. The higher concentration of ascorbic acid, estrogenic substances and beta-sitosterol, vitamins and particular essential amino acids such as methionine, cysteine, tryptophan, and lysine present in MO leaves, pods make it virtually an ideal nutritional supplement.^[7] Some studies showed the hepatoprotective effect of methanolic leaf extract of *Cyathea gigantea* against paracetamol-induced liver toxicity in rats. The paracetamol intoxication leads to histological and biochemical distortion. The methanolic extract of leaves of *C. gigantea* at doses of 100 mg/kg body weight and 200 mg/kg body weight has significant effect on the liver of paracetamol-induced hepatotoxicity model in rats.^[8] Based on the crucial role of oxidative stress in age-related dementia and the antioxidant activities of MO, the enhancement of special memory and neuroprotection of MO leaves extract in an animal model of age-related dementia were determined.^[9] MO is a rich source of essential minerals antioxidants. It has been used in human and animal nutrition. The leaves and flowers are being used by the population with greatly dietary importance.^[10] Hepatoprotective activity of the ethanolic extract of *Nigella sativa* in paracetamol-induced acute hepatotoxicity was studied in rats. Liver histopathology showed marked reduction in sinusoidal dilation, midzonal necrosis, portal triaditis, and occasional apoptosis in *N. sativa* extract treated rats compared to only paracetamol treated rats.^[11] Studies using powdered whole leaf preparations of MO have been published, which have demonstrated antihyperglycemic and antidiabetic activities. A rapidly growing number of published studies have shown that aqueous, hydroalcohol, or alcohol extracts of MO leaves possess a wide range of additional biological activities including antioxidant, tissue protective (liver, kidneys, heart, testes, and lungs), analgesic, antiulcer, antihypertensive, radioprotective, and immunomodulatory actions.^[12] MO has an excellent ability to protect against oxidative damage due to its high polyphenols, flavonoids, and flavonols content. MO was also able to enhance antioxidant status and reduce lipid peroxidation. This herbal product has the potential to be used as an antidiabetic agent in the treatment and managements of diabetes.^[13] Hence, this present study is an attempt to justify the potency of the hydroethanolic extract of MO flower extract as a hepatoprotective agent against APAP-induced liver toxicity.

MATERIALS AND METHODS

Collection of Plant Materials

Flower of MO was collected from Berhampore, Murshidabad, West Bengal, India. The flora of Murshidabad, West Bengal, was used for the identification and authentication of the plant. Collected materials were washed thoroughly in running water, rinsed in distilled water and shade dried in the open air and grinded into powder.

Preparation of the Plant Extract

100 g of the powder form that was prepared from the shaded dried substance was then extracted using 1000 ml of 80% hydroalcoholic solvent (80% ethanol; 20% distilled water). The extract was then filtered and then concentrated.

Experimental Animals

Adult male albino rats weighing between 100 and 120 g of initial body weight were selected and were used in the present experiment. They were housed under standard laboratory conditions with a 12 h daylight cycle and had free access to food and water. They were acclimatized to laboratory conditions for 2 weeks before the commencement of the experiment.

Animals Grouping and Treatment

Twenty-four animals were randomly divided into four groups with each group consisting of six rats. The four groups of rats were subjected to the following oral treatment once a day for 30 days.

Group-I: Rats received normal saline as the control group.

Group-II: Rats received 300 mg/kg body weight of APAP.

Group-III: Rats received 300 mg/kg body weight APAP followed by 150 mg/kg body weight of hepamerz, a hepatoprotective drug.

Group-IV: Rats received 300 mg/kg body weight APAP followed by a hydroethanolic extract of 400mg/kg body weight MO flower.

At the end of the treatment, overnight fasted animals were sacrificed using diethyl ether, followed by cervical dislocation.

Animal Sacrifice and Measurement of Parameters

After completion of 30 days of treatment, the final body weights of all the rats were taken by the electronic balance. The rats were then anesthetized one after another with anesthetic

ether followed by cervical dislocation and blood was collected directly from the hepatic portal vein and allowed to coagulate. Clear serum was collected and stored at 20°C for enzyme assay. Liver of each rat was dissected out and weights were taken with the help of electronic balance. Liver from each experimental animal was processed for histology and 5µ thick sections were taken and stained with hematoxylin and eosin^[14] for further observation. Serum glutamate pyruvate transaminase (SGPT), serum glutamate oxaloacetate transaminase (SGOT), and serum alkaline phosphatase (ALP) were measured of all the control and experimental animals by the supplied standard kit (“COGENT,” Clinical Chemistry division of Span Diagnostics Ltd.), serum glucose was measured using the standard kits (COGENT). The total serum protein was estimated by the Lowry method with a standard curve of BSA.^[15] Serum SOD, catalase activity, and lipid peroxidation level were measured to determine the oxidative stress in all the experimental animals, including the control animals by the methods of Marklund and Marklund,^[16] Beers Jr. and Sizer,^[17] and Buege and Aust,^[18] respectively.

Statistical Analysis

The statistical analysis was carried out by Student’s “*t*” test^[19] to generalize the results of various biochemical parameters of experimental groups in comparison to their respective control group and $P < 0.05$ was considered as a significant result.

RESULTS

Body Weight

Treatment of rat for 30 days with 300 mg/kg body weight of APAP caused no significant changes in body weight gain %

relative to control. There is no significant change found in the Hepamerz and hydroethanolic extract of MO flower treated rats, as shown in Table 1.

Liver Weight

A significant increase ($P < 0.05$) in the liver weight was observed in the group of rats treated with APAP. After the administration of extracts, there was a moderate reduction of liver weight when compared to control rats, as shown in Table 2.

Biochemical Parameters

Serum SGPT level

In rats treated with APAP, SGPT level increased significantly as compared to the control group. On the other hand, a significant decrease ($P < 0.05$) in serum SGPT was observed following the administration of MO extract. The rate of decline in serum enzymes level following administration of MO extract was the same as that of hepamerz, as shown in Table 3.

Serum SGOT level

In rats treated with APAP, SGOT increased significantly as compared to the control group. On the other hand, significant decrease ($P < 0.05$) in serum SGOT was observed following the administration of MO extract. The rate of decline in serum enzymes level following this administration was the same as that of hepamerz, as shown in Table 4.

Serum alkaline phosphatase level

In rats treated with APAP, ALP increased significantly as compared to the control group. On the other hand, a

Table 1: Results of body weight gain % of different experimental groups including the control group. Values are mean±SEM (g%, $n=6$) followed by two-tail *t*-test

Control	Group-I (APAP)	Group-II (APAP+Hepamerz)	Group-III (APAP+M.O)
23.16±0.92	23.17±1.01	23.16±0.72	23.16±0.89

APAP: Acetaminophen, MO: *Moringa oleifera*

Table 2: Results of liver weight of different experimental groups including control group. Values are mean±SEM (g%, $n=6$) followed by two-tail *t*-test

Control	Group-I (APAP)	Group-II (APAP+Hepamerz)	Group-III (APAP+M.O)
5.485±1.03	6.676±0.92	5.842±1.25	5.959±0.87

APAP: Acetaminophen, MO: *Moringa oleifera*

Table 3: Results of SGPT level of different experimental groups including the control group. Values are mean±SEM (IU/L, $n=6$) followed by two-tail *t*-test

Control	Group-I (APAP)	Group-II (APAP+Hepamerz)	Group-III (APAP+M.O)
55.95±1.35	137.41±2.04	72.56±1.78	84.86±1.69

APAP: Acetaminophen, MO: *Moringa oleifera*, SGPT: Serum glutamate pyruvate transaminase

significant decrease ($P < 0.05$) in serum ALP was observed following the administration of MO extract. The rate of decline in serum enzymes level following the administration of this extract was the same as that of hepamerz, as shown in Table 5.

Serum Total Protein

In rats treated with APAP, total protein decreased significantly as compared to the control group. On the other hand, a significant increase ($P < 0.05$) in total serum protein was observed following the administration of MO extract. The rate of increase in serum enzymes level following administration of this herbal extract was the same as that of hepamerz, as shown in Table 6.

Serum Glucose Level

Treatment of rat for 30 days with 300 mg/kg body weight of APAP caused no significant changes in glucose level relative to control. There is also no significant change found in the

Hepamerz and hydroethanolic extract of MO flower treated rats, as shown in Table 7.

Serum SOD Activity

In rats treated with APAP, SOD activity was decreased significantly as compared to the control group. On the other hand, a significant increase ($P < 0.05$) in serum SOD activity was observed following the administration of MO flower extract. The rate of increase in serum enzymes level following administration of this extract was in the same manner as that of Hepamerz effect, as shown in Table 8.

Serum Catalase Activity

In rats treated with APAP, catalase activity was decreased significantly as compared to the control group. On the other hand, a significant increase ($P < 0.05$) in serum catalase activity was observed following the administration of MO flower extract. The rate of increase in serum enzymes level

Table 4: Results of SGOT level of different experimental groups including the control group. Values are mean \pm SEM (IU/L, $n=6$) followed by two-tail t -test

Control	Group-I (APAP)	Group-II (APAP+Hepamerz)	Group-III (APAP+M.O)
64.09 \pm 1.26	192.25 \pm 1.76	84.18 \pm 1.62	87.46 \pm 1.40

APAP: Acetaminophen, MO: *Moringa oleifera*, SGOT: Serum glutamate oxaloacetate transaminase

Table 5: Results of alkaline phosphatase level of different experimental groups including the control group. Values are mean \pm SEM (IU/L, $n=6$) followed by two-tail t -test

Control	Group-I (APAP)	Group-II (APAP+Hepamerz)	Group-III (APAP+M.O)
42.27 \pm 1.73	65.30 \pm 2.21	44.91 \pm 1.43	44.17 \pm 1.74

APAP: Acetaminophen, MO: *Moringa oleifera*

Table 6: Results of serum total protein of different experimental groups including the control group. Values are mean \pm SEM (g/100 ml, $n=6$) followed by two-tail t -test

Control	Group-I (APAP)	Group-II (APAP+Hepamerz)	Group-III (APAP+M.O)
7.06 \pm 0.40	4.15 \pm 0.36	6.84 \pm 0.48	6.23 \pm 0.36

APAP: Acetaminophen, MO: *Moringa oleifera*

Table 7: Results of the serum glucose level of different experimental groups including the control group. Values are mean \pm SEM (g/100 ml, $n=6$) followed by two-tail t -test

Control	Group-I (APAP)	Group-II (APAP+Hepamerz)	Group-III (APAP+M.O)
93.22 \pm 1.25	96.22 \pm 1.25	96.28 \pm 1.26	96.30 \pm 1.29

APAP: Acetaminophen, MO: *Moringa oleifera*

Table 8: Results of serum SOD activity of different experimental groups including the control group. Values are mean \pm SEM (U/ml, $n=6$) followed by two-tail t -test

Control	Group-I (APAP)	Group-II (APAP+Hepamerz)	Group-III (APAP+M.O)
61.52 \pm 1.35	35.64 \pm 1.40	55.23 \pm 1.62	53.83 \pm 1.54

APAP: Acetaminophen, MO: *Moringa oleifera*, SOD: Superoxide dismutase

following administration of this extract was in the same manner as that of heparmerz effect, as shown in Table 9.

Serum Lipid Peroxidation Level

In rats treated with APAP, lipid peroxidation level was increased significantly as compared to the control group. On the other hand, a significant decrease ($P < 0.05$) in serum lipid peroxidation level was observed following the administration of MO flower extract. The rate of decrease in serum enzymes level following administration of this herbal extract was in the same manner as that of heparmerz effect, as shown in Table 10.

Histopathological Effect

Histopathological examination of liver tissue in APAP administered rats showed massive tissue necrosis with loss of cellular architecture and infiltration of neutrophil, macrophages, and lymphocyte. The liver showed congestion, minimal fibrosis in the peripheral area, and degenerative changes in the hepatocytes. Histology of liver sections from APAP+MO extract-treated rats revealed an almost return to normal architecture of hepatic tissues in rats. Similar architecture and cell arrangements were observed in the liver section of rats treated with Heparmerz, as shown in Table 11.

DISCUSSION

The analgesic effect of acetaminophen is probably dependent on the rate and amount of active drug reaching the central nervous system which is believed to cross blood-brain

barrier. It is believed that selective inhibition of the enzyme cyclooxygenase-3 (COX-3) (COX similar to COX-1 and COX-2) in the brain and the spinal cord explains the effect of reducing pain and fever by blocking the production of prostaglandins (PGE-2) as COX plays a key regulatory role in PGs and thromboxane synthesis.^[20] Toxicity from acetaminophen is not from the drug itself but its metabolites, *N*-acetyl-*p*-benzoquinone imine (N acetylimidoquinone/ NAPQI). Acetaminophen biotransformation is depicted in Figure 1.

Acetaminophen administration in the experimental group of animals showed significant alteration in liver weight, serum SGPT activity, serum SGOT activity, ALP activity, and serum total protein along with altered antioxidant enzymes such as SOD and catalase in serum and relative alteration in lipid peroxidation. Body weight gain% and serum glucose concentration were not significantly altered in the experimental group in comparison to their respective control group of animals. The histopathological observation was also significantly changed in APAP administered animal group.

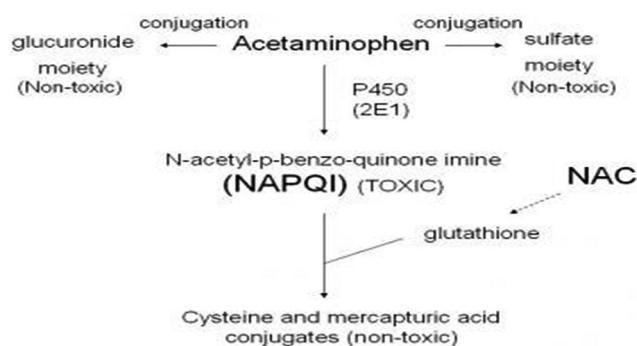


Figure 1: Acetaminophen metabolism

Table 9: Results of serum catalase activity of different experimental groups including the control group. Values are mean±SEM (U/ml, n=6) followed by two-tail *t*-test

Control	Group-I (APAP)	Group-II (APAP+Heparmerz)	Group-III (APAP+M.O)
49.22±1.67	32.86±1.58	42.36±1.45	41.49±1.29

APAP: Acetaminophen, MO: *Moringa oleifera*

Table 10: Results of serum lipid peroxidation level of different experimental groups including the control group. Values are mean±SEM (n moles TBARS/50 µl, n=6) followed by two-tail *t*-test

Control	Group-I (APAP)	Group-II (APAP+Heparmerz)	Group-III (APAP+M.O)
0.136±0.0015	0.199±0.0018	0.142±0.0015	0.145±0.0017

APAP: Acetaminophen, MO: *Moringa oleifera*

Table 11: Results of the histopathological study of liver of various microscopic observation of different experimental animal groups including the control group

Microscopic observation	Control	Group-I (APAP)	Group-II (APAP+Heparmerz)	Group-III (APAP+M.O)
Necrosis	–	+++	++	++
Central venule dilation	Normal	++	+	+
Sinusoidal dilation	Normal	++	+	++

APAP: Acetaminophen, MO: *Moringa oleifera*

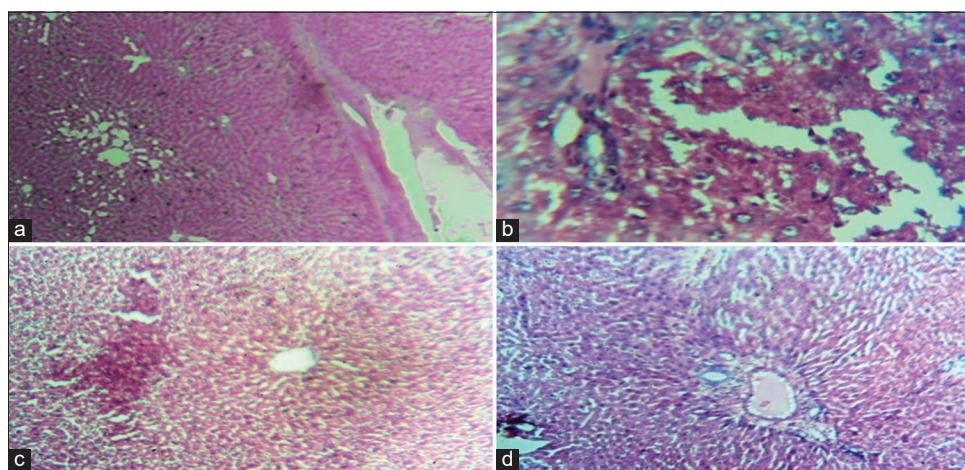


Figure 2: Necrosis in liver cells (a) normal liver section of control; (b) acetaminophen-induced liver section; (c) Hepamerz-treated liver section; (d) *Moringa oleifera* flower treated liver section

Hepamerz has been administered in another group of animals in this present study, and it was observed that the improvement has taken place in all the APAP-induced deteriorated parameters in experimental animals. Hepamerz not only neutralizes toxins and arrest them to be cleared from the body acting as detoxicating agents but also actively helps in the restoration of cell and natural function of liver that provides the hepatoprotective effect.

After the administration of hydroethanolic extract of MO flower, it has been observed that body weight gain% has been altered insignificantly in all the experimental groups in comparison with the control group. Liver weight was increased significantly indicating the hepatic disorder after APAP induction in the experimental group in comparison with the control group. Hepamerz and MO flower extract supplementation have shown significant alteration in liver weight toward the control group accordingly. SGPT is thought to be concerned with the integrity of the mitochondria.^[21] and it is also abundant in liver and acts as a marker of metabolic activity.^[22] Acetaminophen-induced significant alteration in SGPT suggests metabolic impairment. Significant repairing mechanism has been observed after Hepamerz and MO flower extract supplementation in the present study. SGOT has integrity with lysosomes^[23] and adrenal corticoids stimulates SGOT activity.^[24] Acetaminophen administration showed a significant increase in serum SGOT level indicating metabolic disruption. Supplement of Hepamerz and MO flower extracts in the experimental groups counteracted the effect of APAP significantly in the present study. Serum ALP has also been changed after APAP administration in the same manner as SGPT and SGOT. Effect of Hepamerz and MO flower extract in experimental animals also showed improvement toward normal level of this hepatic enzyme. Serum total protein was significantly decreased after APAP application in experimental animals in comparison to the control group. Supplementation of Hepamerz and MO flower extract has restored the total protein level significantly in the present study. Hence, it indicates that, besides Hepamerz,

the herbal product, MO flower extract also helps in normal functioning of the protein after restoring its level in serum. Besides these altered biochemical parameters, serum glucose concentration was not hampered after APAP administration as well as supplementation of Hepamerz and MO flower extract in the present study. Superoxide is produced as a by-product of oxygen metabolism and, if not regulated, causes many types of cell damage.^[25] As a result of APAP application, the serum SOD activity was decreased in a significant manner in comparison to the control group animals. Hepamerz and MO flower extract supplementation along with APAP caused significant increase in serum SOD activity in experimental animals. Hence, it can be said that APAP induced liver toxicity has been well protected by MO flower extract. Catalase catalyzes the decomposition of hydrogen peroxide to water and oxygen^[26] and serves as an important enzyme in protecting the cell from oxidative damage by reactive oxygen species. The present study showed that APAP increased the oxidative stress by decreasing the catalase activity. It has also been shown that Hepamerz and MO flower extract has hepatoprotective role against APAP induced oxidative damage. In addition, end-products of lipid peroxidation may be mutagenic and carcinogenic.^[27] For instance, the end-product malondialdehyde reacts with deoxyadenosine and deoxyguanosine in DNA. The present study showed increased lipid peroxidation level after APAP administration in comparison with the control group of animals. On the other hand, Hepamerz and MO flower extract supplementation has counter balanced the hazardous end product of lipid peroxidation generated by APAP significantly showing their prominent hepatoprotective efficacy. As the histopathology is concerned, all the effects and recoveries after supplementation of acetaminophen, hepamerz and *Moringa oleifera* flower extract, have been compared with the liver section of control animals [Figure 2a]. The necrotic effect has been found after APAP administration [Figure 2b] which has been repaired by Hepamerz [Figure 2c] and MO flower extract supplementation [Figure 2d]. Central venule dilation and sinusoidal dilation were also remarkable on APAP application. This damage was

effectively repaired by Hepamerz and MO flower extract supplementation along with APAP in the present study.

CONCLUSION

Our findings have suggested that *Moringa oleifera* flower extract, has a potential role in therapeutic properties against chemically induced acute liver injuries in rats. This finding confirmed that hydroethanolic extracts are useful in reducing APAP-induced acute liver toxicity and were comparable with Hepamerz. Although Hepamerz is an expensive medicine and is not affordable to everyone in our society. However, MO is easily available and not expensive. Hence, in the near future, after further detailed observation, this herbal product may be used for hepatic toxicity management.

ACKNOWLEDGMENT

We are grateful to all the respected teachers and other support staff of K. N. College, Berhampore, Murshidabad, West Bengal, India, for their kind support.

FINANCIAL SUPPORT AND SPONSORSHIP

Nil.

CONFLICTS OF INTEREST

There are no conflicts of interest.

REFERENCES

1. Lim YS, Kim WR. The global impact of hepatic fibrosis and end-stage liver disease. *Clin Liver Dis* 2008;12:733-46, 7.
2. Graudal N, Leth P, Mårbjerg L, Galløe AM. Characteristics of cirrhosis undiagnosed during life: A comparative analysis of 73 undiagnosed cases and 149 diagnosed cases of cirrhosis, detected in 4929 consecutive autopsies. *J Intern Med* 1991;230:165-71.
3. Anwar F, Latif S, Ashraf M, Gilani AH. *Moringa oleifera*: A food plant with multiple medicinal uses. *Phytother Res* 2007;21:17-25.
4. Dièye AM, Sarr A, Diop SN, Ndiaye M, Sy GY, Diarra M, et al. Medicinal plants and the treatment of diabetes in Senegal: Survey with patients. *Fundam Clin Pharmacol* 2008;22:211-6.
5. Khalafalla MM, Abdellatef E, Dafalla HM, Nassrallah AA, Aboul-Enein KM, Lightfoot DA, et al. Active principle from *Moringa oleifera* Lam leaves

effective against two leukemias and a hepatocarcinoma. *Afr J Biotechnol* 2010;9:8467-71.

6. Fakurazi S, Sharifudin SA, Arulselvan P. *Moringa oleifera* hydroethanolic extracts effectively alleviate acetaminophen-induced hepatotoxicity in experimental rats through their antioxidant nature. *Molecules* 2012;17:8334-50.
7. Adejumo OE, Kolapo AL, Folarin AO. *Moringa oleifera* Lam. (Moringaceae) grown in Nigeria: *In vitro* antisickling activity on deoxygenated erythrocyte cells. *J Pharm Bioallied Sci* 2012;4:118-22.
8. Kiran PM, Raju AV, Rao BG. Investigation of hepatoprotective activity of *Cyathea gigantea* (Wall. ex. Hook.) leaves against paracetamol-induced hepatotoxicity in rats. *Asian Pac J Trop Biomed* 2012;2:352-6.
9. Sotalangka C, Wattanathorn J, Muchimapura S, Thukham-mee W. *Moringa oleifera* mitigates memory impairment and neurodegeneration in animal model of age-related dementia. *Oxid Med Cell Longev* 2013;2013:695936.
10. Sharifudin SA, Fakurazi S, Hidayat MT, Hairuszah I, Moklas MA, Arulselvan P. Therapeutic potential of *Moringa oleifera* extracts against acetaminophen-induced hepatotoxicity in rats. *Pharm Biol* 2013;51:279-88.
11. Kushwah DS, Salman MT, Singh P, Verma VK, Ahmad A. Protective effects of ethanolic extract of *Nigella sativa* seed in paracetamol induced acute hepatotoxicity *in vivo*. *Pak J Biol Sci* 2014;17:517-22.
12. Stohs SJ, Hartman MJ. Review of the safety and efficacy of *Moringa oleifera*. *Phytother Res* 2015;29:796-804.
13. Omodanisi EI, Aboua YG, Oguntibeju OO. Assessment of the anti-hyperglycaemic, anti-inflammatory and antioxidant activities of the methanol extract of *Moringa oleifera* in diabetes-induced nephrotoxic male Wistar rats. *Molecules* 2017;22:E439.
14. Llewellyn BD. Nuclear staining with alum hematoxylin. *Biotech Histochem* 2009;84:159-77.
15. Lowry OH, Rosebrough NJ, Farr AL, Randall RJ. Protein measurement with the folin phenol reagent. *J Biol Chem* 1951;193:265-75.
16. Marklund S, Marklund G. Involvement of the superoxide anion radical in the autoxidation of pyrogallol and a convenient assay for superoxide dismutase. *Eur J Biochem* 1974;47:469-74.
17. Beers RF Jr., Sizer IW. A spectrophotometric method for measuring the breakdown of hydrogen peroxide by catalase. *J Biol Chem* 1952;195:133-40.
18. Buege JA, Aust SD. Microsomal lipid peroxidation. *Methods Enzymol* 1978;52:302-10.
19. Das D, Das A. *Statistics in Biology and Psychology*. 4th ed. Kolkata: Academic Publishers; 2005. p. 117-26.
20. Arroyo V, Ginés P, Rimola A, Gaya J. Renal function abnormalities, prostaglandins, and effects of nonsteroidal anti-inflammatory drugs in cirrhosis with ascites. An overview with emphasis on pathogenesis. *Am J Med* 1986;81:104-22.

21. Wilkinson JM. Principles and Practices of Diagnostic Enzymology. United Kingdom: Edward Arnold Publishers; 1976. p. 87-95.
22. Das D. Biochemistry. 10th ed. Kolkata: Academic Publishers; 2000. p. 132-4.
23. Lee D, Holland RK, Groufsky AK. Integrity of lysosomes in the isolated perfused rat liver before and after exposure to dimethylsulphoxide. *Cryobiology* 1979;16:18-23.
24. Forsham PH. The adrenals. In: William RH, editor. *The Text Book of Endocrinology*. 4th ed. Philadelphia, PA: W. B. Saunders; 1968. p. 310.
25. Hayyan M, Hashim MA, AlNashef IM. Superoxide ion: Generation and chemical implications. *Chem Rev* 2016;116:3029-85.
26. Chelikani P, Fita I, Loewen PC. Diversity of structures and properties among catalases. *Cell Mol Life Sci* 2004;61:192-208.
27. Marnett LJ. Lipid peroxidation-DNA damage by malondialdehyde. *Mutat Res* 1999;424:83-95.

Source of Support: Nil. **Conflicts of Interest:** None declared.